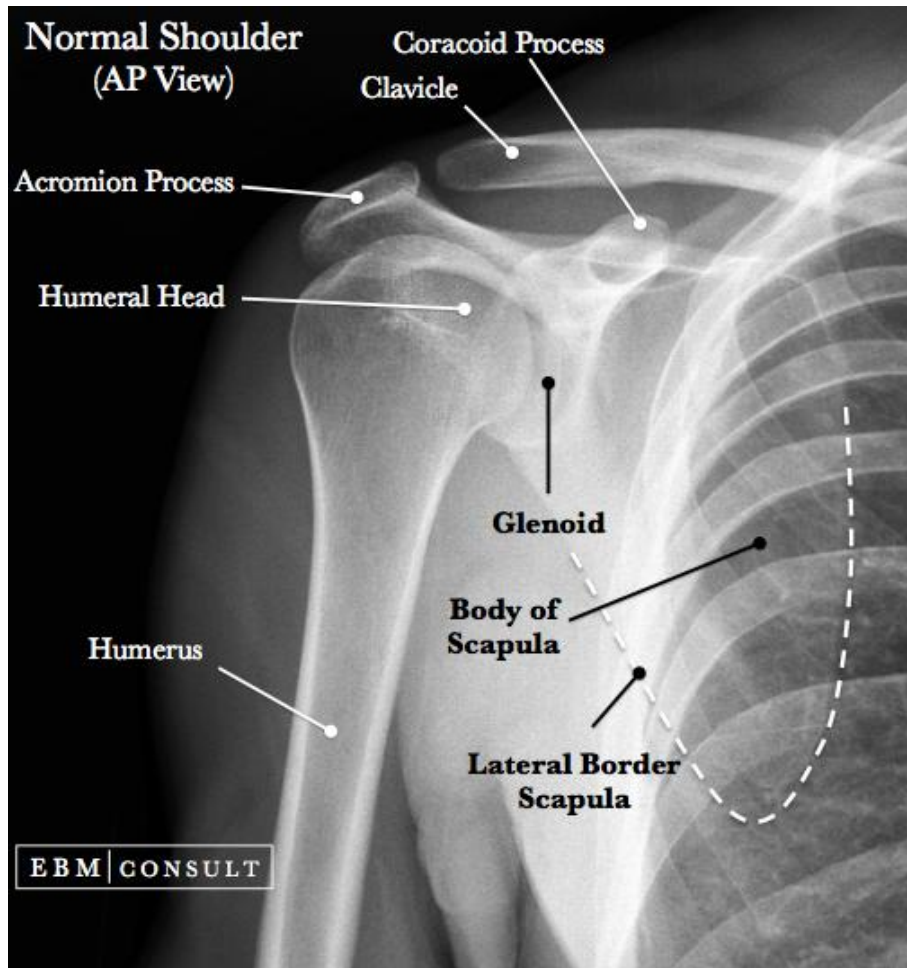
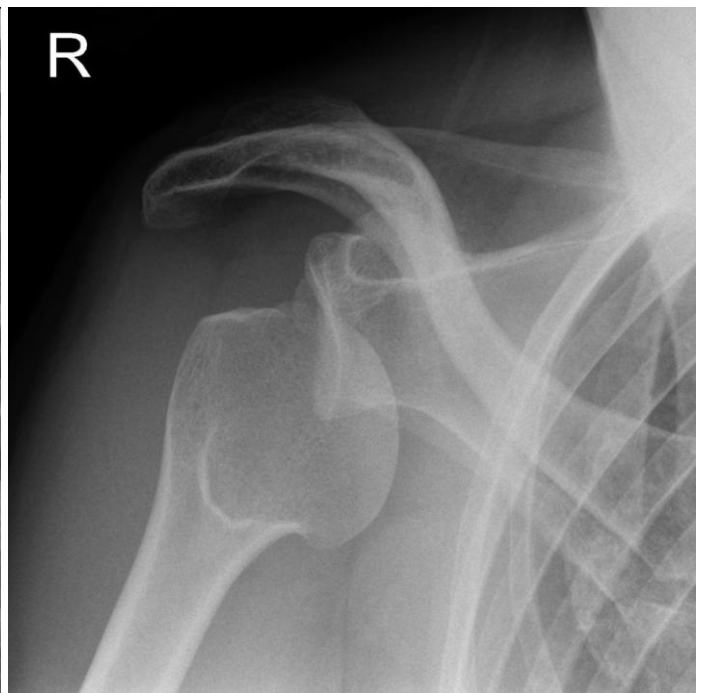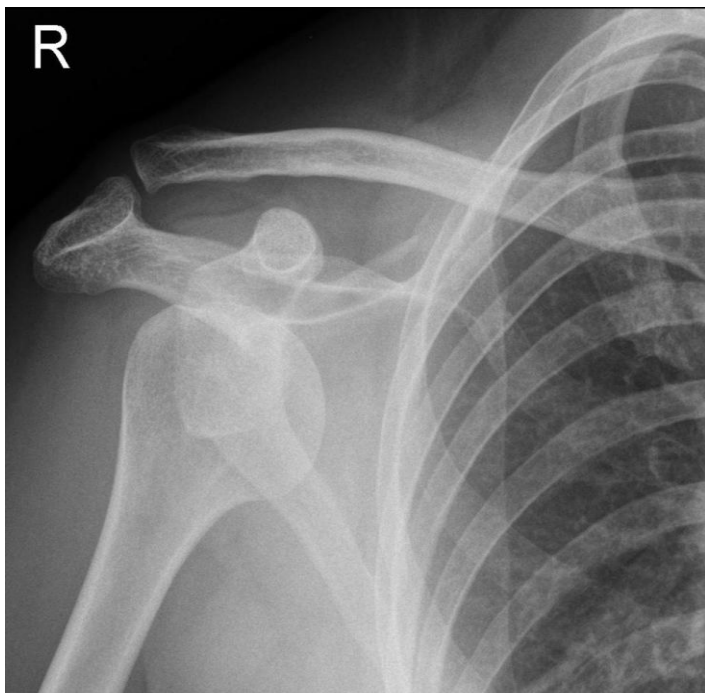
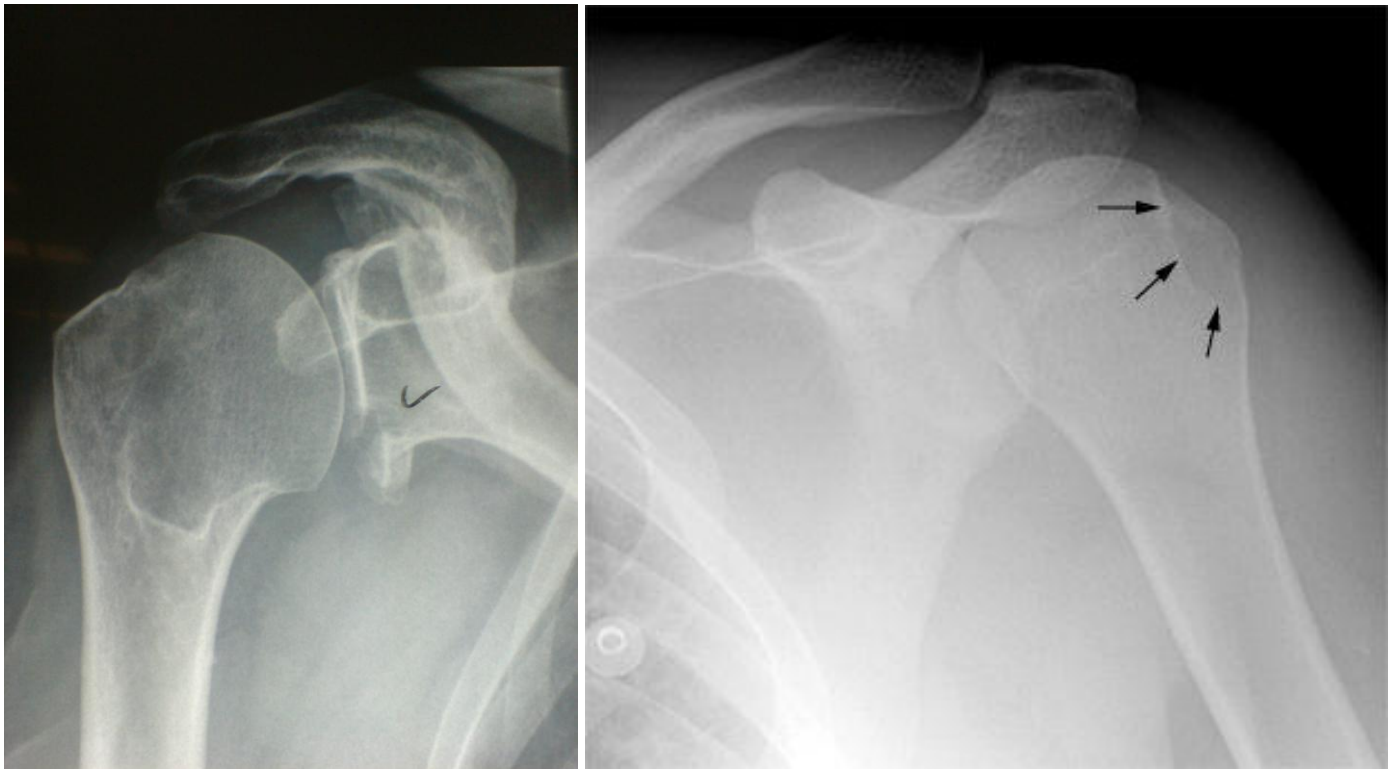


MUSCULOSKELETAL
SHOULDER XR INTERPRETATION



Above: normal right AP shoulder. Below: anterior shoulder dislocations.

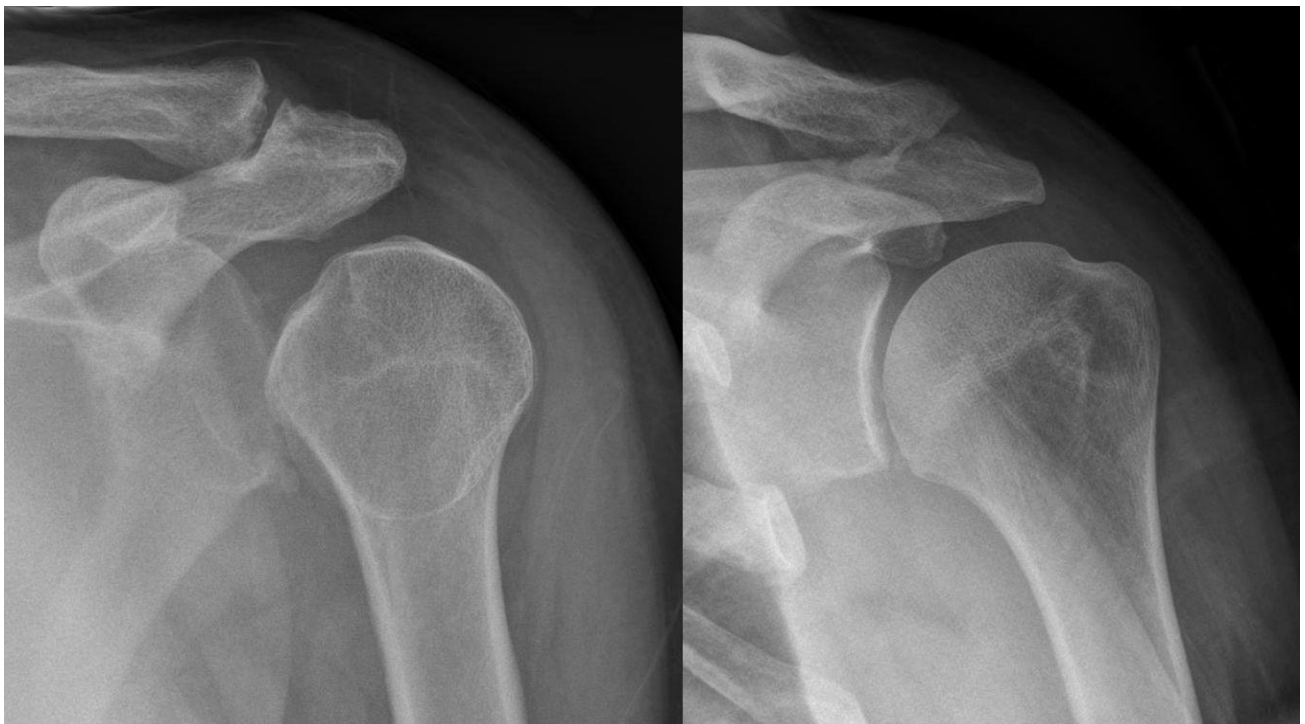



Above left: Bankart lesion. Above right: Hills-Sachs Deformity.

Bankart Lesion: a piece of bone is avulsed from the glenoid rim during anterior dislocation. It may lead to greater instability of the shoulder joint and may require surgery.

Hills-Sachs Deformity: cortical depression of the humeral head created by the glenoid rim during dislocation. They may contribute to instability and sometimes require surgery.



Above: posterior shoulder dislocation before and after reduction.