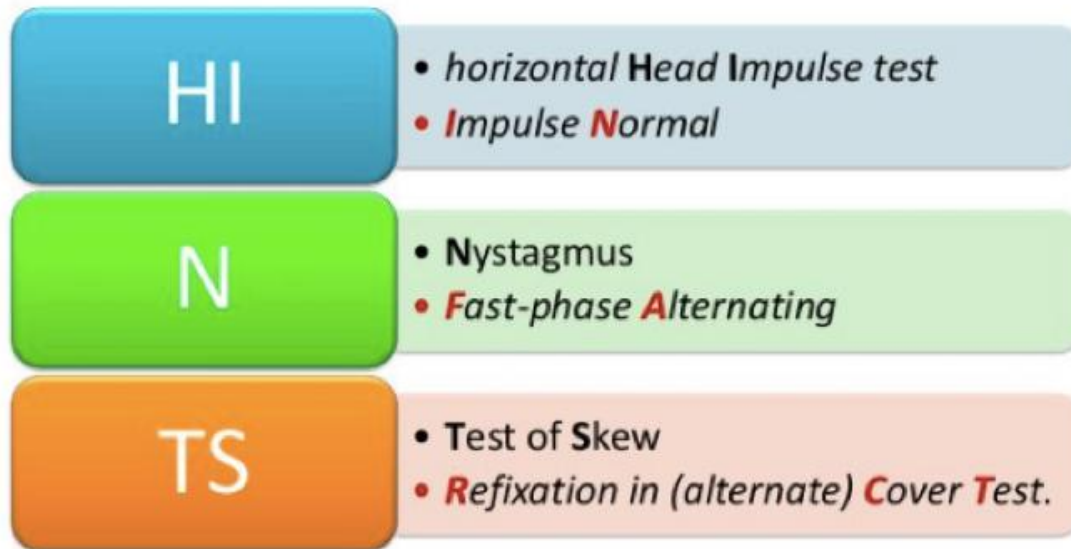


Head Impulse-Nystagmus-Test of Skew.

HINTS to **INFARCT**



Absence of ALL of these features (IN-FA-RCT) essentially rules out a central etiology