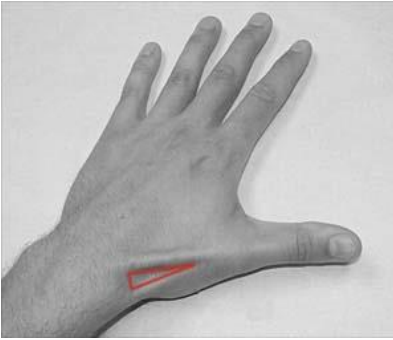
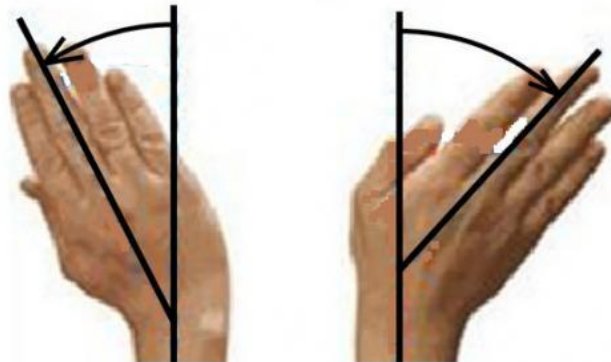


# MUSCULOSKELETAL SCAPHOID FRACTURE

Following a FOOSH, examine for pain associated with any of the following:



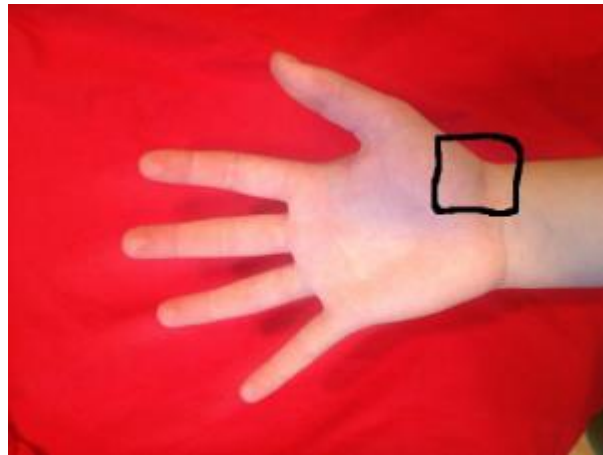
Palpation of anatomical snuffbox



Radial Deviation      Ulnar Deviation

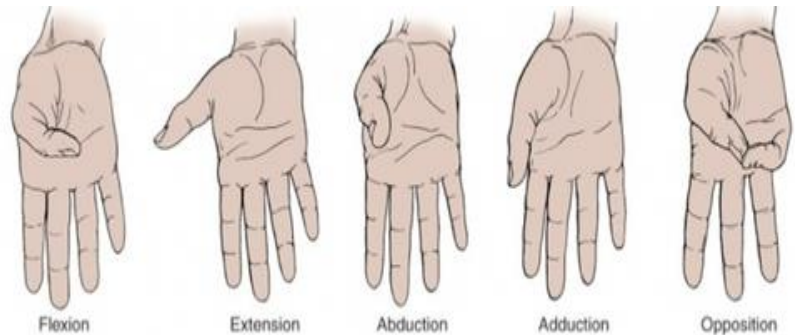
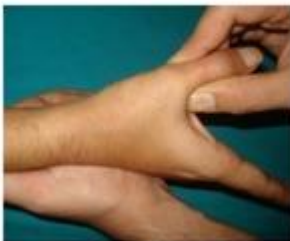

Thumb- index finger pinch



Direct palpation of the scaphoid tubercle

Scaphoid compression test



Decreased range of thumb movements

If any of these present get scaphoid views on xray, if no fracture seen:

- Thumb splint
- Acute MRI scaphoid
- Virtual fracture clinic follow- up