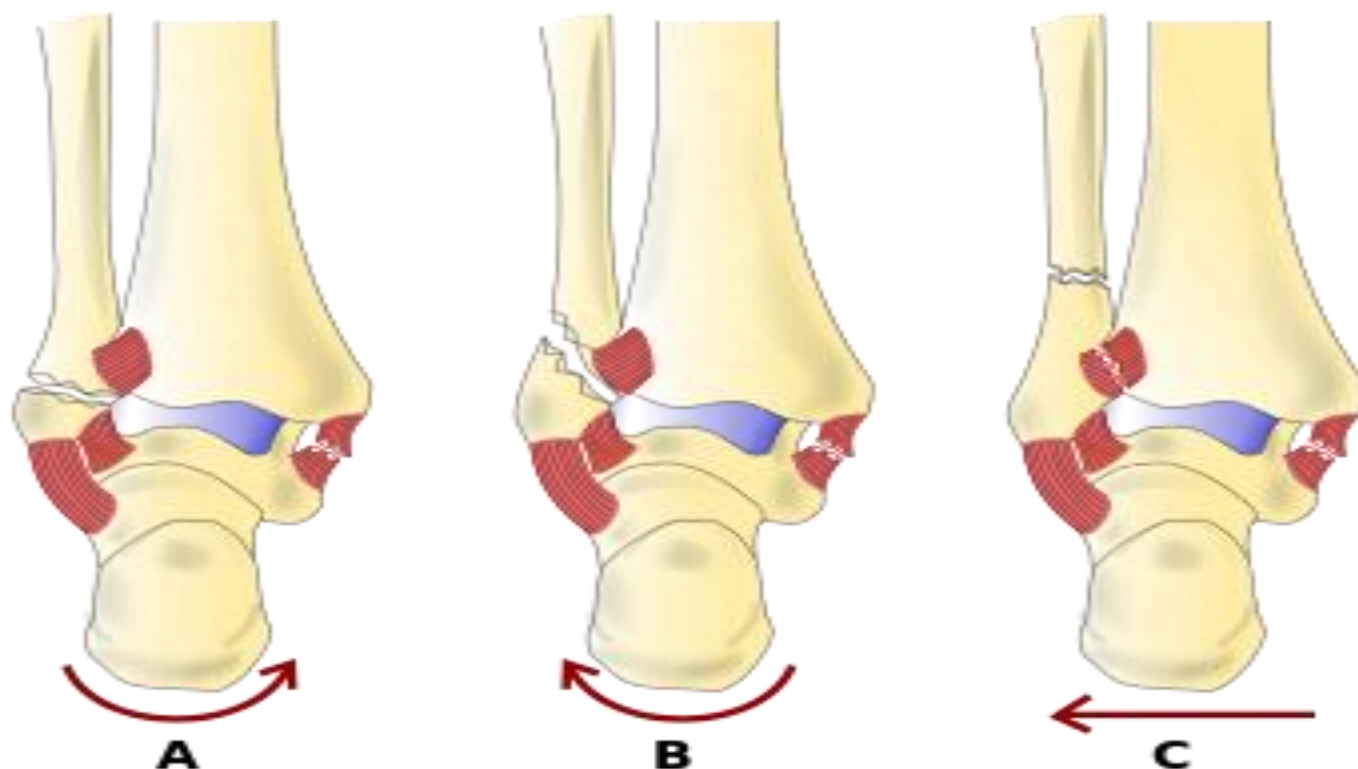


## MUSCULOSKELETAL

### DANIS- WEBER ANKLE FRACTURE CLASSIFICATION



#### Type A

Fracture of the lateral malleolus **distal** to the syndesmosis

Features:

- Below level of ankle joint
- Tibiofibular syndesmosis intact
- Deltoid ligament intact
- Medial malleolus often fractured
- Usually stable

#### Type B

Fracture of the fibula **at the level** of the syndesmosis

Features:

- At level of ankle joint, extending superiorly and laterally up fibula
- Tibiofibular syndesmosis intact or only partially torn, but no widening of distal tibiofibular articulation
- Medial malleolus may be fractured
- Deltoid ligament may be torn
- Variable stability

#### Type C

Fracture of the fibula **proximal** to the syndesmosis

Features:

- Above the level of the ankle joint
- Tibiofibular syndesmosis disrupted with widening of the distal tibiofibular articulation
- Medial malleolus fracture or deltoid ligament injury present
- Unstable- requires ORIF