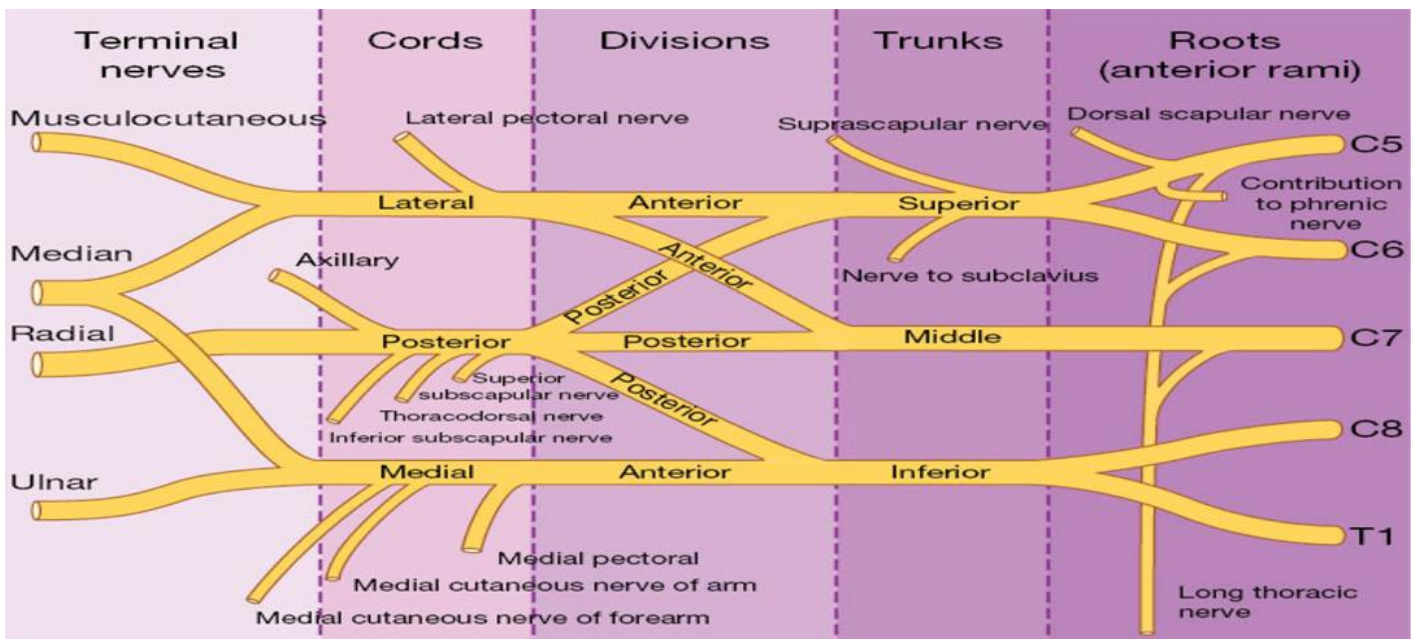
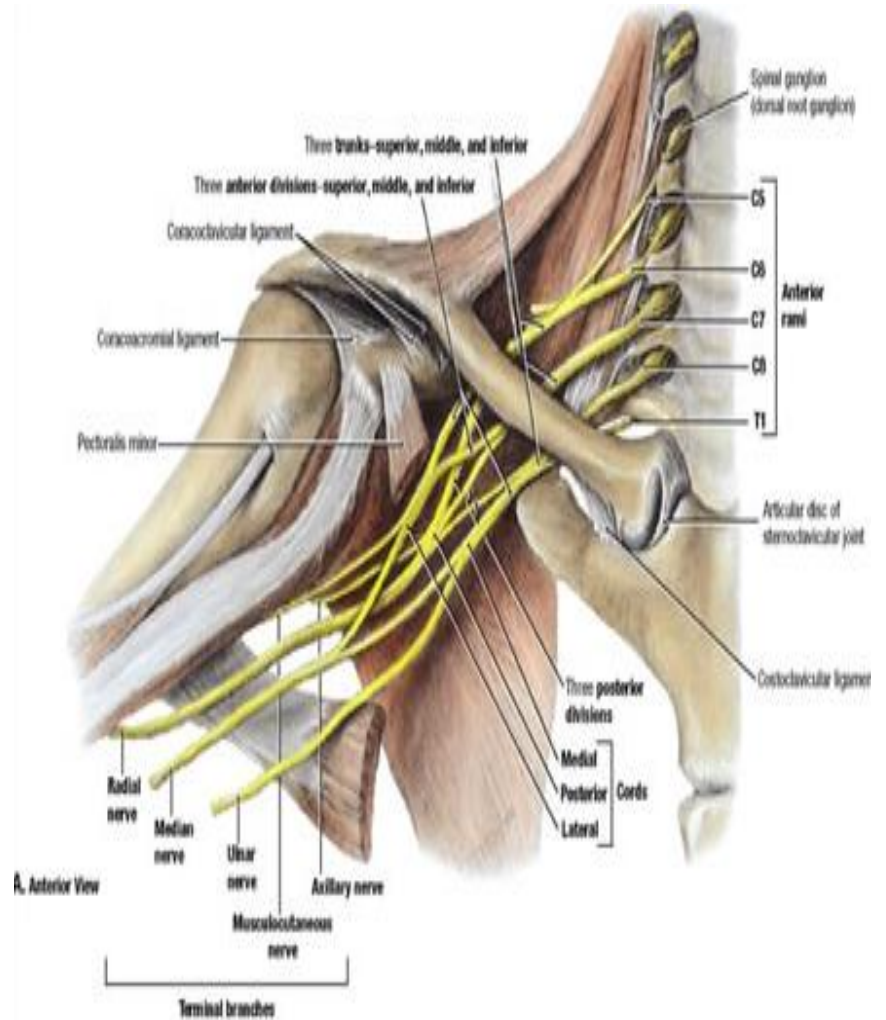


MUSCULOSKELETAL BRACHIAL PLEXUS

- The brachial plexus is a complex network of nerves, originating from fifth cervical nerve to first thoracic nerve (C5- T1).
- It passes through the cervicoaxillary canal, under the clavicle, over the first rib and into the axilla
- It supplies sensory and motor function to the upper limb and chest.
- It is divided into
 - 5 roots
 - 3 trunks
 - 6 divisions
 - 3 cords
 - 5 terminal branches
- It gives off multiple pre-terminal branches along the way



Terminal Branch	Nerve roots	Sensory innervation	Motor innervation
Axillary	C5, C6	Regimental badge area	Deltoid, Teres minor
Musculocutaneous	C5-7	Anterolateral forearm	Biceps brachii, Brachialis, Coracobrachialis
Radial	C5- T1	Posterolateral forearm & wrist, posterior upper arm	Triceps brachii, Extensor muscles of forearm, Brachioradialis, Anconeus
Median	C5- T1	Lateral 2/3 of hand and 1 st - 4 th fingertips	Forearm flexors, Thenar eminence, 1 st & 2 nd lumbricals
Ulnar	C8/ T1	Medial dorsum of hand, dorsum of medial 1.5 fingers & Palm	Hypothenar eminence, Forearm flexors (some), Adductor pollicis, Interossei, 3 rd & 4 th lumbricals

